

# WHAT'S NEW, PUSSYCAT?

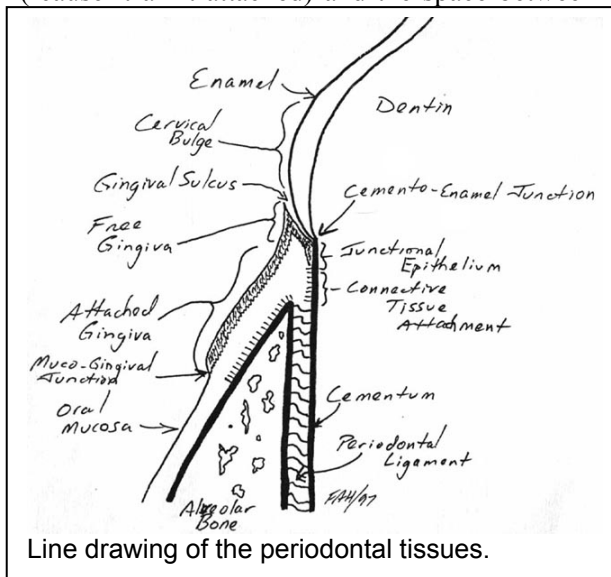
## News about Feline Resorptive Lesions?

Over the past many years there have been a number of papers presented and published examining the problem of feline odontoclastic resorptive lesions (RLs), and though the body of knowledge has been growing, the pieces of the puzzle have not been adding up to a clear understanding of the condition. In the past year or so, there have been a number of new studies presented that show the promise of bringing the other bits together so that a plausible picture may be forming.

Before I embark on this discussion, we need to review a bit of anatomy to make sure we are all speaking the same language.

The crown of the tooth is that part covered by enamel and the root is covered by cementum. Where the crown and root meet is the neck, cervix or cemento-enamel junction (CEJ). The bulk of the tooth is composed of dentin and inside the tooth is a hollow chamber containing the dental pulp.

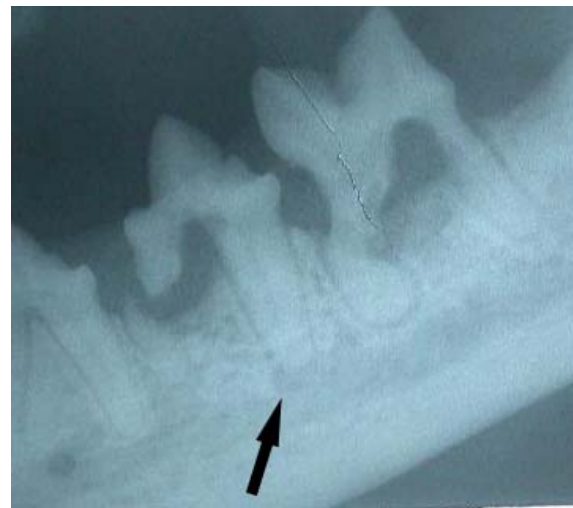Most of the root is situated in a depression in the bone known as the alveolus. The most coronal portion of the root extends above the margin of the alveolar bone. Gingiva is a tough tissue that lies against the tooth and alveolar bone. The free-gingival margin is above the CEJ, but gingiva does not attach to enamel, so the gingiva above the CEJ is known as the free gingiva ('cause it ain't attached) and the space between



gingiva and enamel is known as the gingival sulcus. From the CEJ to the crest of the alveolar bone, the gingiva should be firmly attached to the root cementum in a tight collar completely encircling the tooth. It is this collar of gingival attachment that isolates the periodontal ligament space from oral bacteria.

Within the alveolus, there is a space between the root and bone (the periodontal ligament space), occupied by the periodontal ligament, which attaches to the bone and cementum. The periodontal ligament space appears radiographically as a fine radiolucent line following the contour of the root.

I need to quote an axiom that must be kept in mind. *A little knowledge is a dangerous thing.* What follows will be a condensed review of some recent papers. Much of this information is very new and needs further study before we can change our approach to treating resorptive lesions. I do not want you going off half-cocked.



Intra-oral radiograph of Type I resorptive lesions affecting the left mandibular fourth premolar and molar teeth. The defects are centered on the cervical region of the teeth and are associated with periodontal bone loss. Beyond the confines of the lesion, the roots look perfectly normal with normal radiodensity, clearly visible endodontic chambers and a clearly visible periodontal ligament space between root and bone. Once the pulp chamber is breached by the lesion, these teeth often develop endodontic disease. The original film showed an obvious radiolucency around the apex of the distal root of the fourth premolar (black arrow).

One more introductory note (which will be repeated because it is sooooo important).

***INTRA-ORAL DENTAL RADIOGRAPHY IS ESSENTIAL FOR THE ACCURATE ASSESSMENT AND PROPER TREATMENT OF RESORPTIVE LESIONS.***

I am not just saying this to encourage you to refer (though that would be nice) – it just makes sense. I doubt any of you would even consider treating a fractured limb without diagnostic radiographs. Nor would you do an exploratory laparotomy without radiographs. Without dental radiographs, you cannot know what you are getting into or when you have gotten out.

### Two Types of RLs

**Gregg DuPont** has described two distinct types of resorptive lesions based on clinical, radiographic and histologic appearance.

**Type I** lesions are the less common ones associated with moderate to severe gingivitis and/or periodontitis. They typically start at the

CEJ and can extend in all directions from that starting point. There is typically little or no root resorption evident beyond the confines of the lesion. The cause of these lesions might well be local inflammatory reaction due to gingivitis or periodontitis.

As type I lesions are often associated with periodontitis and endodontic disease, these teeth must be entirely extracted. It is not permissible to leave any remnants of these roots behind. The good news is that the presence of a periodontal ligament (i.e., the lack of ankylosis) makes these roots fairly easy to extract. The bad news is that the resorptive process usually creates serious weak spots on the roots, so the roots break and then it is necessary to surgically remove the root remnants. Having a pre-operative dental x-ray lets you know where the weak spots are.

**Type II** lesions are not only more common, they are also more frustrating to deal with. However, these are the ones that we may be getting closer to understanding.

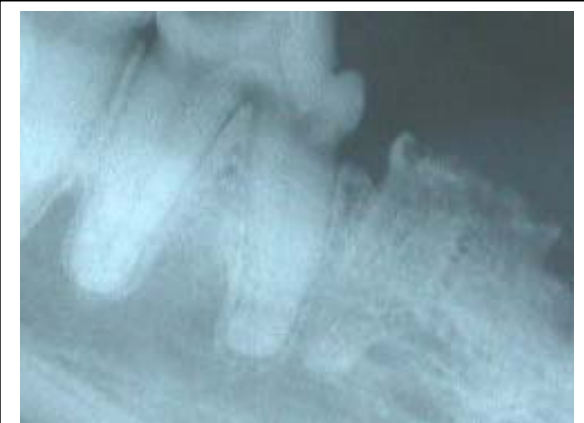Type II lesions are not generally associated with endodontic disease or periodontitis, though there may be localized gingivitis or granulation tissue

in and around the lesion itself. These lesions seem to be able to arise at any location on the root and are associated with extensive root resorption, loss of periodontal ligament and ankylosis.

### New Histology Studies

**Steinberg** looked at 80 clinically normal teeth taken from cats that had at least one clinical RL and found that 100% of these teeth had microscopic evidence of resorption and these lesions were found primarily in the non-cervical region of the root. This suggests that if these cats live long enough, every single tooth will eventually succumb to resorptive lesions. Taken further, it could be said that if they live long enough, every cat will develop type II RLs.

**Gorrel and Larsson** also did a study looking for microscopic lesions on the roots of cat teeth. They harvested 56 teeth that appeared clinically and radiographically free of RLs. Of these, 43 teeth (group A) were taken from cats that had a clinical RL on at least one tooth and 13 teeth (group B) were taken from cats with no clinical or radiographic evidence of RLs on any teeth.



A grade 5, type II lesion of the right mandibular third premolar tooth. Most of the crown has fallen away, though some remains. The roots have been largely resorbed and replaced by bone-cementum tissue. There is no periodontal ligament space visible. Frequently the gingiva will appear to have healed over these lesions, though there is often a fistula and persistent inflammation. In this film, there is no periodontal bone loss and no evidence of endodontic disease. This lesion seems particularly common on the canine teeth of cats.

Twenty six teeth from group A and one tooth from group B showed microscopic evidence of external root resorption.

Among the salient observations of this study were the following:

- the cervical cementum on the roots of teeth from RL cats was thicker and more irregular than that found on the roots of teeth taken from RL-free cats.
- The periodontal ligament around non-ankylosed resorptive lesions was narrow and the fibers arranged vertically (rather than the normal horizontal or oblique arrangement). The ligament around ankylosed lesions was grossly abnormal with edematous vascularized tissue.
- Teeth from RL cats were much more likely (60%) to have microscopic resorptive lesions than teeth from RL-free cats (8%). These microscopic lesions were all located at the mid root or apical portion of the root and were not associated with inflammation.
- Healed cemental lesions covered by intact periodontal tissue was seen in some cases.
- Ankylosis was associated with formation of reparative bone-cementum tissue filling in the space vacated by the disappearing root tissue.

These findings suggest that type II lesions start within the cementum of the root and in some cases they may heal spontaneously. The other big surprise was the finding that these early lesions are not associated with inflammation. It seems that as long as the lesion remains on the root **below the level of gingival attachment and protected from oral bacterial contamination**, there is no inflammation. Once the lesion extends through the gingival attachment and comes in contact with oral bacteria, inflammation develops as a result of the lesion, not its cause.

### New Biochemical Studies

**Alex Reiter** has done a study which may prove to be the key to unlocking the mystery. He looked at the serum concentration of calciotropic hormones in cats with RLs. What he found was that cats with RLs had significantly higher

serum levels of 25 hydroxyvitamin D than cats without RLs.

As he points out, rather than asking “why do some cat teeth undergo resorption?”, we should ask “why do some cat’s teeth not undergo resorption?”. After all, teeth are made of the same tissues as bone and it is constantly undergoing remodeling. Normally, the roots of permanent teeth are considered to be resistant to resorption because of a protective organic matrix. If this matrix is lost or becomes calcified, then odontoclasts (which are virtually identical in every way to osteoclasts) can attack the root surface.

Reiter proposes that hypercementosis, osteoid production along the socket wall or gradual calcification of the periodontal ligament might be the trigger. He further postulates that this is caused by hypervitaminosis D. Another study found that excess administration of vitamin D or its metabolites to experimental animals resulted in dental and periodontal changes very similar to those seen around teeth affected by RLs. Since cats cannot manufacture vitamin D, they must take it in from dietary sources.

Looking at the vitamin D content in canned cat foods, Reiter found that 20 of 49 brands (41%) had in excess of 30 times the vitamin D requirements of 250IU/kg diet dry matter and 31% actually exceeded the AAFOO maximum **level of 10 000 IU/kg diet dry matter**.

**Colin Harvey** and others have done some work looking at a biphosphonate drug (alendronate) that is used in humans to prevent osteoporosis. One study found that the drug bound very heavily to alveolar bone and root cementum – that’s good news as it means we can get this drug right where we want it.

The next study looked at the effect this drug might have on established type II lesions over time. Using colony cats at research facilities, he quantified the size of lesions found. The cats then received alendronate for a year and the lesions were re-measured. In the vast majority of cases, the lesions were no larger a year later and in some cases they were actually smaller. In the control cats, the lesions increased in size as predicted. These findings suggest that alendronate may someday be useful to prevent

the progression of very early lesion and even in preventing them completely.

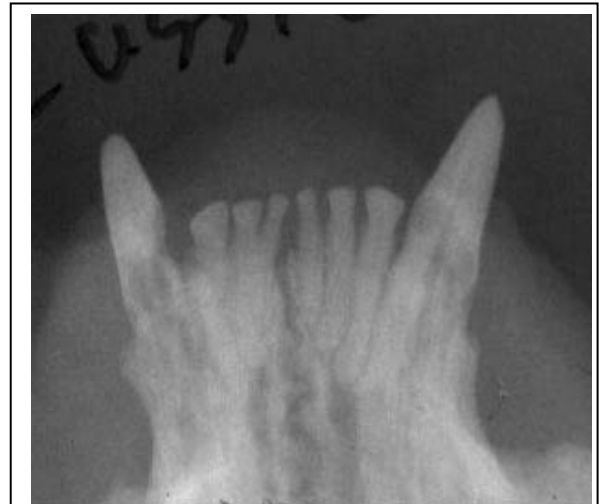What does all this add up to?

It is too early to be certain and we should not get overly excited as yet, but here is what seems to be coming into focus.

- Type I lesions are possibly the result of gingival and periodontal inflammation and arise at the cervical region of the tooth. From there, they may extend up the crown and/or down the root. Prevention would be based on maintaining good oral hygiene. Treatment of detectable lesions is complete extraction of the tooth and its roots (leave nothing behind).
- Type II lesions are a non-inflammatory resorption that begins within the socket or at least below the level of gingival attachment and may be triggered by vitamin D toxicity. Only after the lesion enlarges sufficiently to break through the gingival attachment to become contaminated with oral bacteria does inflammation become a factor. Treatment is still extraction and in my view it should be complete removal of all dental tissues (more on this later).
- The only way to distinguish between a type I lesion and a type II lesion is with intra-oral dental radiography.
- It is possible that we may find a way of preventing the more common type II lesions either by reducing dietary intake of vitamin D and its metabolites or by administration of a biphosphonate drug.

### More on the treatment of Type II RLS

About ten years ago, **Gregg. DuPont** published a paper in the *Journal of Veterinary Dentistry* suggesting that *in very particular circumstances*, it **might** be permissible to leave some root remnants in place when extracting teeth with resorptive lesions. Unfortunately, this message got bastardized until the word on the street was that it was okay to just snap off the crowns and leave the rest to sort itself out. This gets back to the axiom about a little bit of knowledge being dangerous.

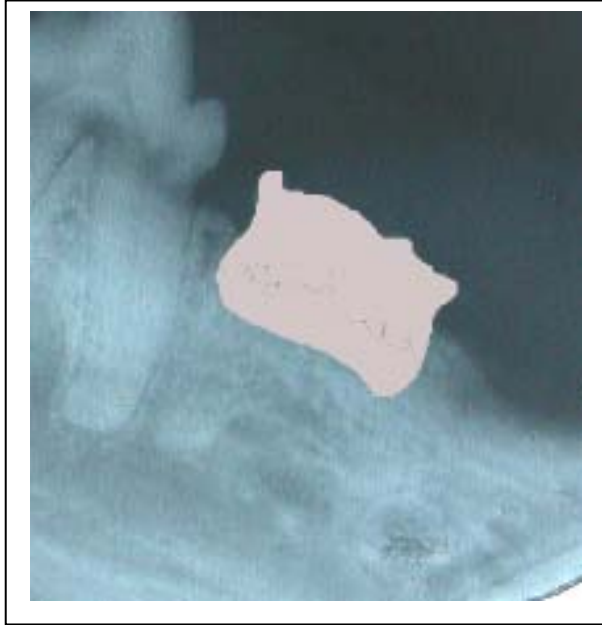


Type II RLS often affect the roots of canine teeth. Only in advanced cases do the lesions extend above the gingival attachment to become detectable on probing. Intra-oral radiographs are the key to detecting these.

I will be the first to admit that veterinary dentists do not have all the answers with regard to RLS yet, however, we do always take dental radiographs as part of our evaluation of RLS and that is absolutely essential.

As I have stated, type I lesions should be completely extracted. Also, teeth with any radiographic or clinical evidence of deep periodontal or endodontic disease should be extracted completely. Teeth in cats who are positive for FeLV, FIV or who have a history of chronic oral inflammatory disease (lymphoplasmacytic gingivitis/stomatitis) should be completely removed.

If a tooth has a type II lesion without periodontal or endodontic disease (as confirmed radiographically) and the root appears to have been largely replaced by new bone-cementum tissue, then it might be permissible to leave a little of this tissue in the socket. The theory goes that the lesions are non-inflammatory and the tissue is healing the defect. My worry is that the lesion has been chronically exposed to oral bacteria by the time the lesion is detected and so I expect that bacterially induced inflammation must extend at least part way down the "root". Therefore, my approach is still to remove all identifiable dental tissue and then suture the wound closed.



Even those who advocate the more conservative approach of “intentional root retention” agree that removing just the crown is not enough. In the picture on page 4, we can see that there is still some coronal enamel at the most distal aspect of the tooth and there are also portions of the root projecting above the alveolar crest. Much of the root tissue has been replaced by bone-cementum tissue and so the roots appear as ghosts. The gingiva overlying this tooth typically would have a fistula and so there is ongoing bacterial invasion. Left on its own, the rest of this tooth will likely resorb, but in the meantime, there is an open and contaminated wound with inflammation and pain. At the risk of being repetitive, my approach would be to reflect gingival flaps, remove all visible or radiographically detectable dental tissues, smooth the bone and suture the wound with 5-0 monofilament absorbable.

The other way some people would manage this lesion would be to reflect the gingival flaps and then just remove the portion I have shaded in the picture on page 7 while leaving the buccal and lingual alveolar plates in tact. Next, they would smooth the alveolar margins and suture. They would always document this radiographically and fully disclose to the owners that this has been done, that it is still a “new” technique and that radiographic and clinical follow-up is required.

How do I want you to manage RLs?

In my fantasy world, you would just refer them all to me.

If you are going to treat cats with RLs here is what you have to do:

- Radiograph every tooth in the head (even those that appear to be missing) and examine each tooth subgingivally with a dental explorer. If you are not going to radiograph, then do not try to treat these cats, just refer them to someone who will radiograph them.
- For type I lesions, extract the entire tooth and root, smooth off the alveolar bone and suture the wound closed with a fine absorbable monofilament.
- For type II lesions, extract as much of the tooth as you can without causing excessive trauma (that is a judgment call), being sure to at least get everything above the alveolar crest and 1 – 2 millimeters into the socket before smoothing the bone and suturing as above.
- Plan to re-examine and re-radiograph annually as cats that have had one lesion will almost certainly get others sooner or later.
- Send the animals home with analgesics (I like meloxicam) for at least four days and put them on softened food for 14 days.
- Antibiotics are for the treatment of infection, not for the prevention of infection. When I do oral surgery, I remove the infected tissue and so only rarely do I feel the need to send home antibiotics.