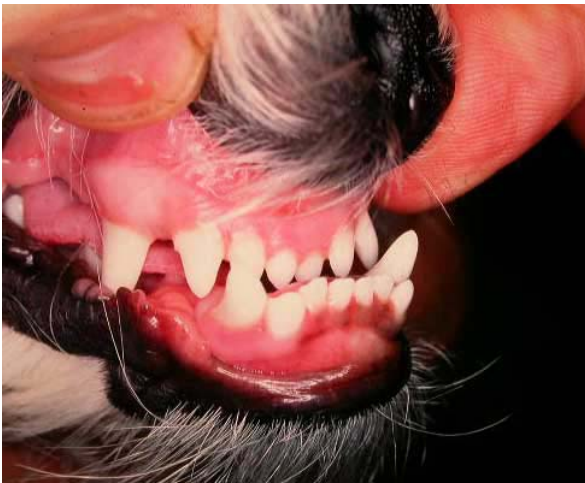

## FOCUS ON: THE BOXER

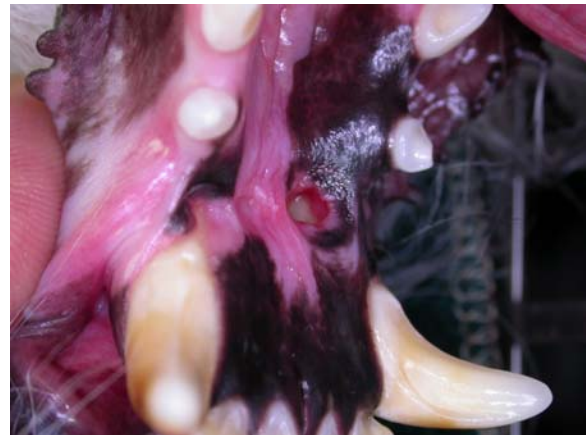I have had the distinct pleasure of seeing an abundance of Boxers recently. Sure, they have lots of problems, but I do not think I have ever met one I did not like. They are such a happy, out-going breed and their enthusiasm for life is rather infectious. Unfortunately, their mouths are usually a real mess. The good news is that we can usually do something about the mouth. I would like to take a few columns now to outline a few of the common problems I see in Boxers. Many of these problems are also very common in other brachycephalic breeds and may can occur in any breed. But if you are seeing Boxers, look carefully for the following problems. They are present far more commonly than you think.

### Class III Malocclusion:

By design, Boxers (and Bull dogs, Lhasas, Shih Tzus...) have a maxilla that is too short relative to the mandible. This form of skeletal deformity results in a Class III Malocclusion. In very minor cases, the incisors may be in normal scissors alignment and you have to look closely at the canine and premolar relationships to pick up these ones. In Boxers, it is never subtle or minor – they always have their upper incisors *behind* the lower incisors. This is referred to as anterior cross bite. While it is a breed standard and purposely selected for, it often causes significant disease.



I know, this is not a Boxer but it is a Class III malocclusion and the photo clearly show how the maxillary central and intermediate incisors are going to cut into the floor of the mouth – “Ouch”.



This animal was also not a Boxer, but he had a Class III malocclusion. You can see the trauma to the soft tissue on the floor of the mouth caused by the upper incisors. On the left side, the hole went right through the soft tissue and bone to expose the roots of the canine tooth and the lateral incisor – “Ouch” again.

In the normal occlusion of the dog, the only tooth-to-tooth contact should be between the maxillary and mandibular molars. In no other area of the mouth are the teeth actually supposed to touch. With anterior cross bite, the maxillary incisors may contact the mandibular incisors or the gingiva on the floor of the mouth and/or may dig into the gingiva and the structure of the lower canine teeth on the lingual side. All of this traumatic tooth-to-tooth and tooth-to-soft tissue contact causes pain. It can lead to periodontal disease of the lower canines and incisors, fracture and wear of any of the involved teeth and endodontic disease.

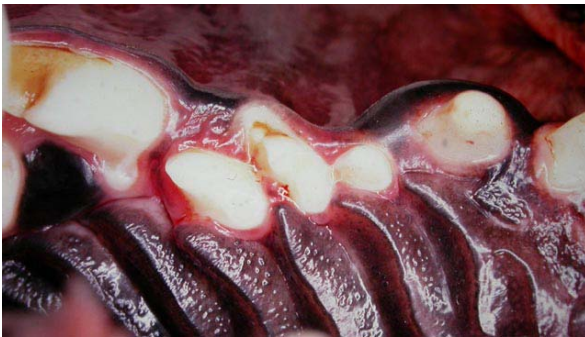Whenever there is abnormal and traumatic tooth-to-tooth or tooth-to-soft tissue contact some form of treatment is indicated to alleviate this trauma and the pain it causes. Ideally, this should

be done very soon after the adult teeth erupt – before permanent damage has been done to the teeth and surrounding tissues.

Treatment options vary depending on several factors and may include reshaping teeth (for minor contacts) or selective extraction of teeth (in more severe cases). Deciding which treatment is most appropriate is almost always best done with the patient under general anesthesia, to allow an unhindered and unhurried view of the situation.

### Dental Crowding:

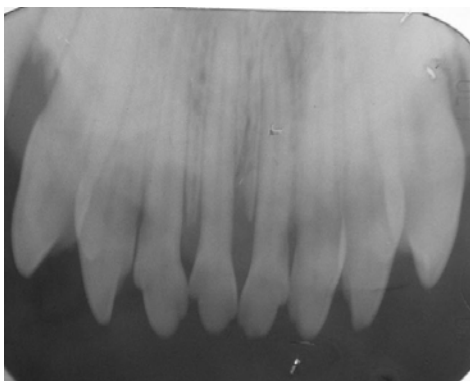
Boxers (and all brachycephalics) do not have enough room in their maxilla to accommodate all of the teeth. Therefore, it is very common for there to be severe crowding of the premolars, often with the third premolar rotated as much as 90 degrees. The crowding dramatically increases the risk of early onset of periodontal disease. While homecare can help slow this down a bit, the tooth brush has trouble reaching all the areas of liability. Therefore, selective extraction of some teeth can dramatically improve the prognosis for the teeth left behind. Again, this is best done shortly after permanent tooth eruption *before* periodontal disease has a chance to get established. If three teeth are crowded together and you remove the middle one early, the other two have a chance. If you “wait-and-see” you are more likely to have to remove all three.



Brachycephalics of all types are very prone to dental crowding of the maxillary premolars. This is a huge risk factor for the early and uncontrollable development of periodontal disease. In this dog, early selective extraction of the first and third premolars will dramatically improve the prognosis for the second and fourth premolars.

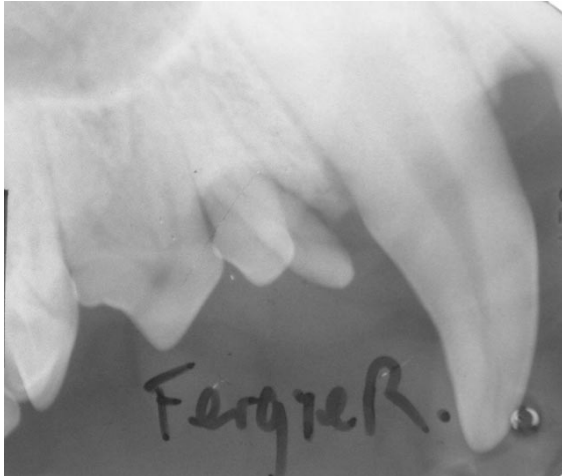### Supernumerary Teeth:

A dog is supposed to have three incisors per quadrant. In Boxers, it is not uncommon for them to have four incisors in one or more quadrant. Because their faces are rather broad and their incisors relatively small (in general), there is often room to accommodate these extra teeth, but careful evaluation of the situation is in order to determine if there is indication for selective extraction or not.



The Boxer in the radiograph to the left had eight maxillary incisors. Even though she has broad face, there were too many teeth for the space available. The most lateral incisor on both sides was removed.

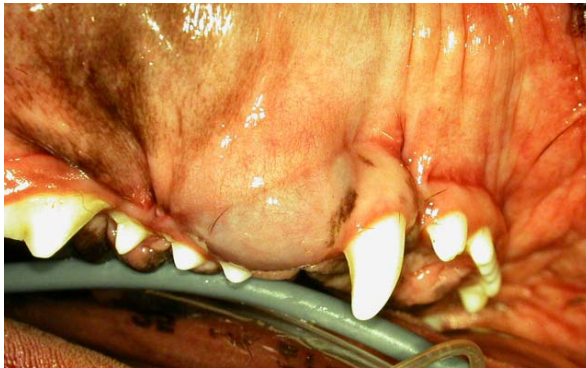The other *very* common finding in Boxers is supernumerary first premolar teeth, especially in the maxilla. This almost always causes serious crowding problems. I frequently find Boxers that have **three** first premolars in a quadrant, and they just do not fit. Selective extraction is **definitely** in order to alleviate the crowding.



This boxer had two right maxillary first premolars. Though she was less than a year-old at presentation, you can see how the crowding has already resulted in considerable bone loss around both of the first premolars and the mesial root of the second premolar.

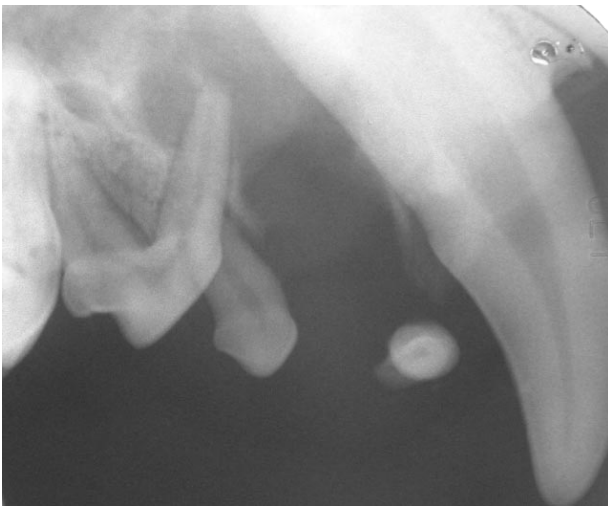### Impacted or Unerupted Teeth:

Sometimes a Boxer looks like it has the proper number of first premolars, but if you take radiographs, you will often find the supernumerary one is unerupted and this can be a serious problem.



This one-year-old Boxer has a swelling behind the canine tooth. At first glance, it appears that all teeth have erupted, so a cyst around an unerupted tooth seems unlikely.

Next we see her radiograph with an unerupted supernumerary first premolar floating freely within the dentigerous cyst. Fortunately, the bone loss was relatively minor in this case and she only had to lose the first premolars and the second premolar. A bone graft and some time allowed for excellent bone fill and salvage of the canine tooth.



The crown of an unerupted tooth is surrounded by a sac of epithelial tissue – what was once the enamel organ. Normally, when a tooth erupts, the sac tears open, but if the tooth does not erupt, it remains intact. Frequently, these vestigial sacs of epithelium will become secretory and start to fill with fluid, forming a dentigerous cyst. As they expand, they cause the surrounding bone to disappear. Eventually they break through the bone and cause an expansion in the overlying soft tissue. This is when it might become apparent on visual oral

examination. However, by the time the cyst is large enough to be seen visually, it has already caused a lot of bone destruction.

Treatment involves surgical removal of the unerupted tooth as well as the cyst lining and any adjacent teeth that have lost their bone support.

Prevention is preferable to treatment. All Boxers should have intra-oral radiographs before 8 months of age to look for and identify any unerupted teeth so that they can be removed before large cyst have a chance to form.

By the way, it is not just the first premolar that might be unerupted and the problem of unerupted teeth is not exclusive to Boxers. Every animal should have an oral inventory done around six months of age and any apparently missing teeth call for radiographs to look for hiding teeth.

#### Deep Palatal Rugae:

The compression of the Boxer maxilla takes place mostly anterior to the upper fourth premolars, which is why this is the area where we see the most dental crowding and rotations. While the bone is compressed, the soft tissue covering the hard palate is not. Therefore, the palatal rugae in this area are typically very large, with high peaks and deep valleys. Food, hair and bacteria accumulate at the bottoms of these deep valleys and cause irritation.

While it is feasible to surgically reduce the depth of the rugae, a more conservative measure will often help. Have the owners sweep the roof of the mouth with a tooth brush or use a WaterPik™ set low to clean the folds out on a daily basis.